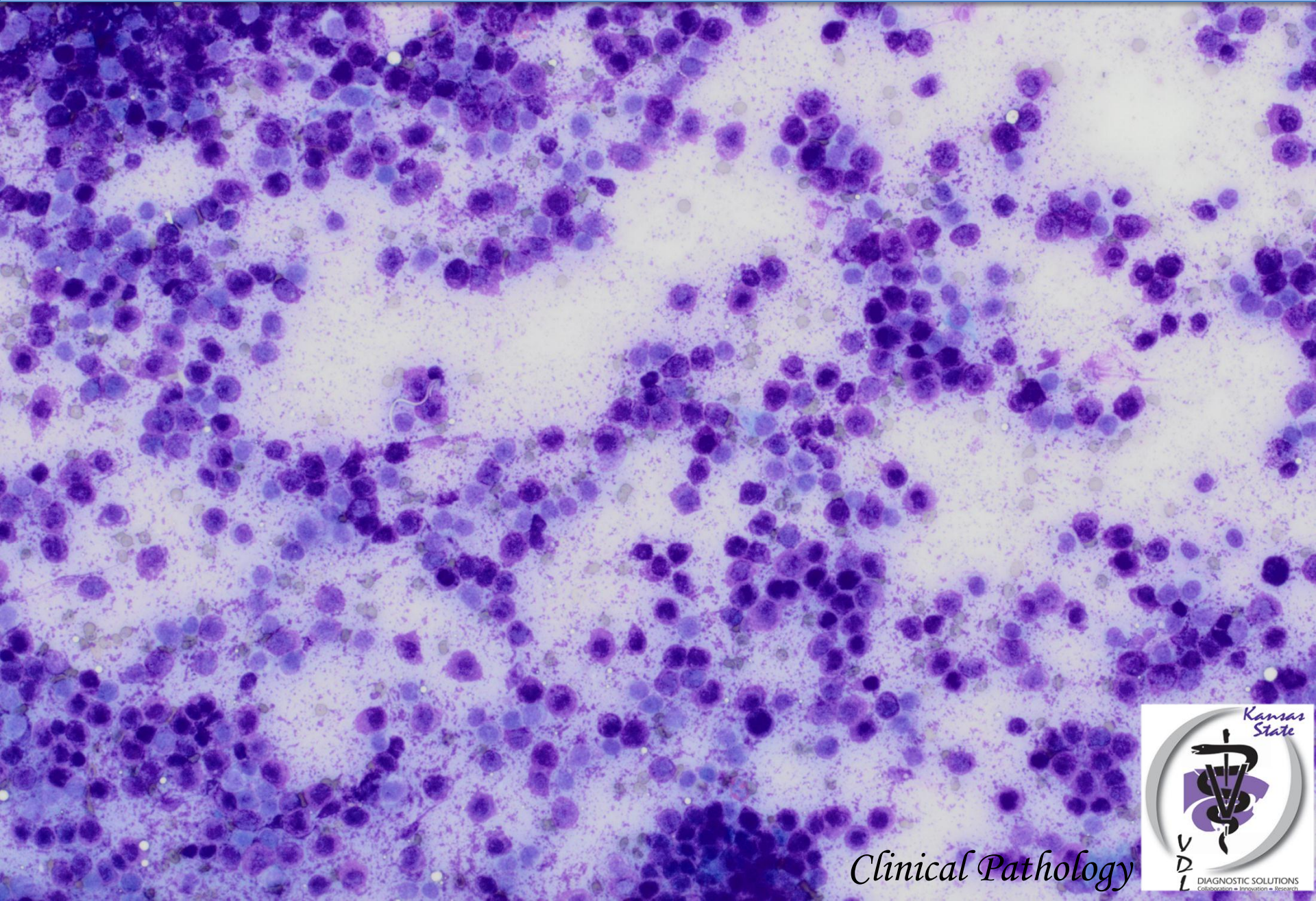


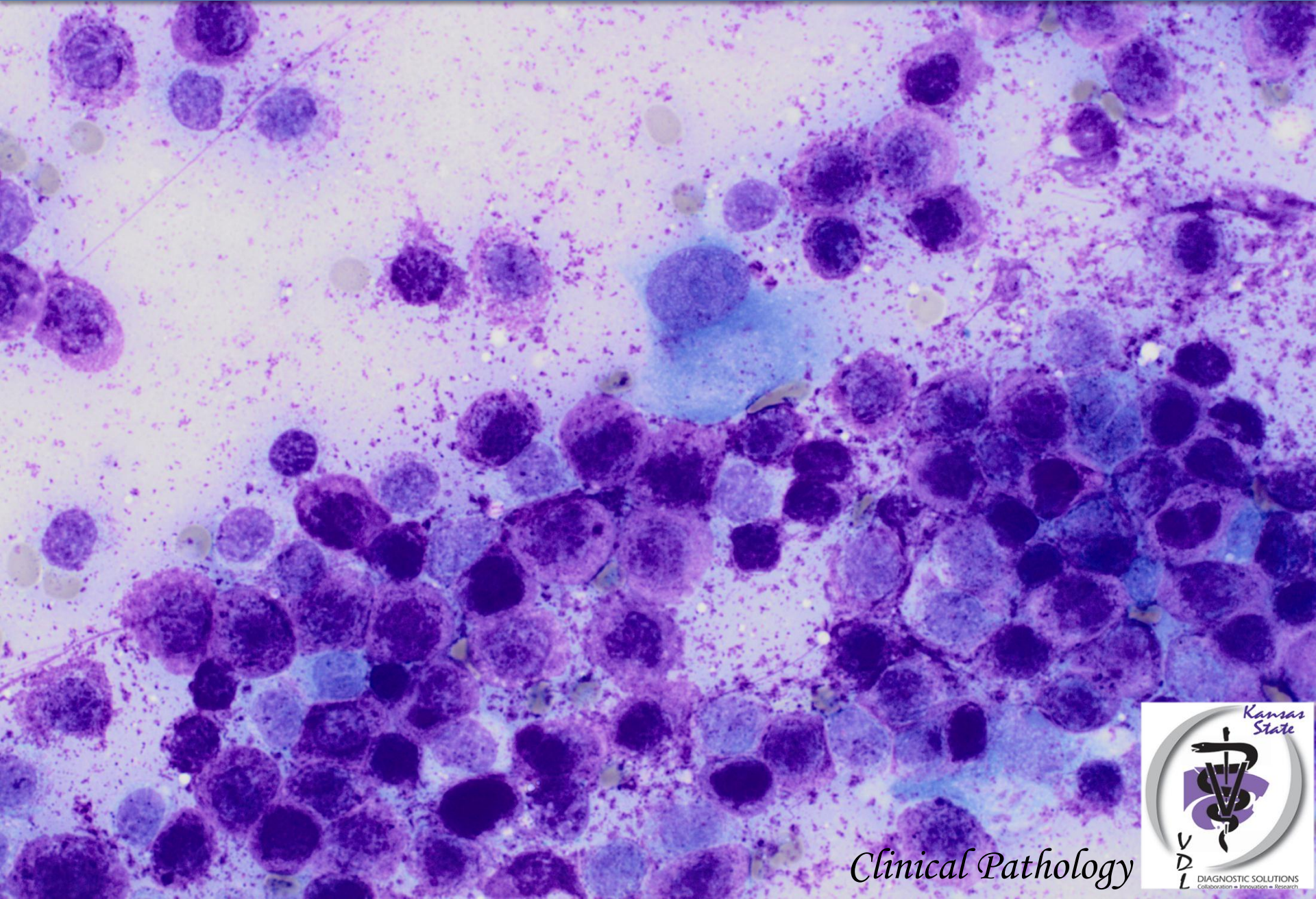
Aspirate from a cutaneous mass in a 7-year-old ferret



Clinical Pathology



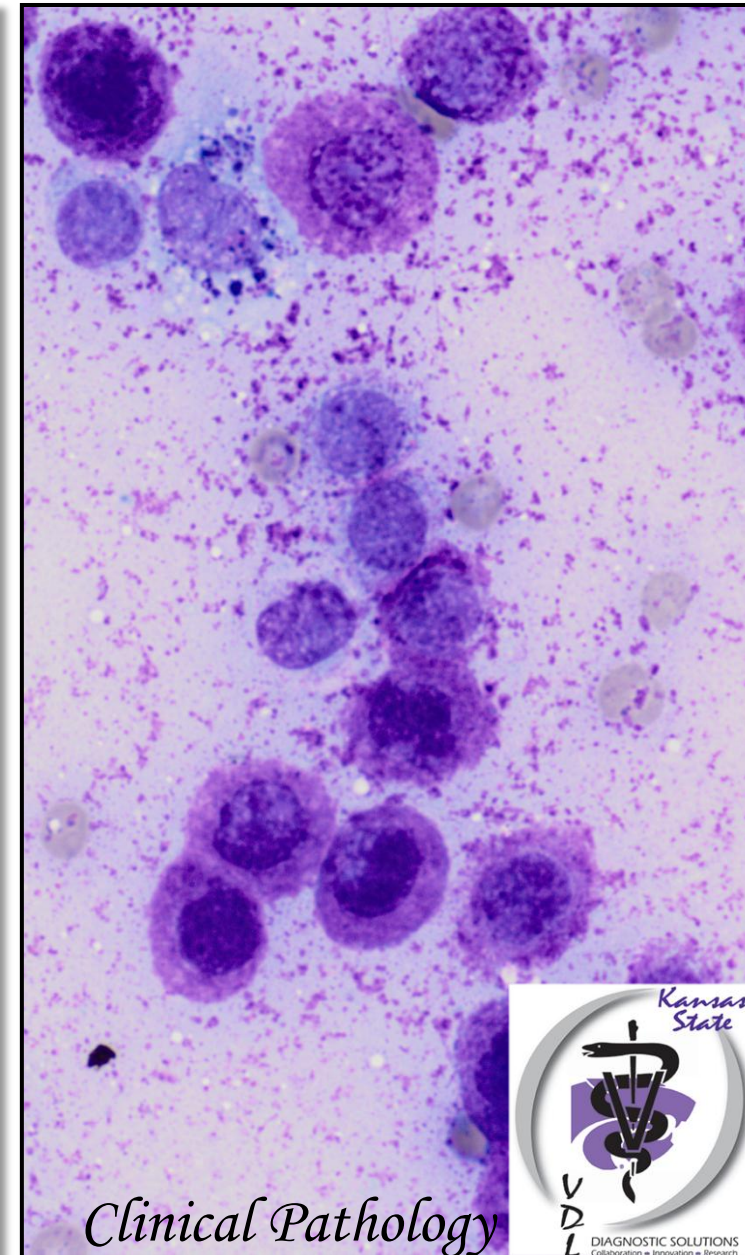
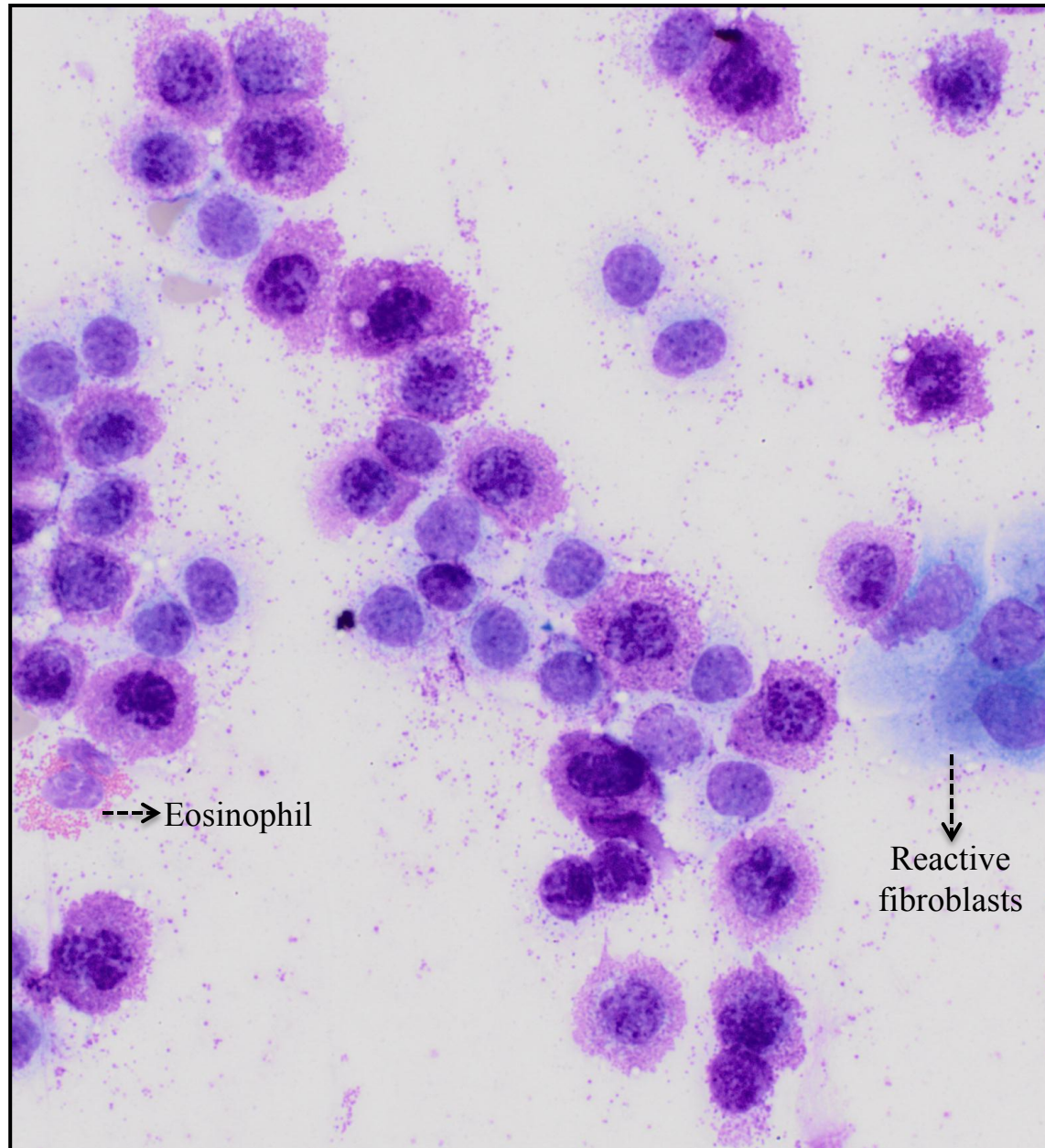
Aspirate from a cutaneous mass in a 7-year-old ferret



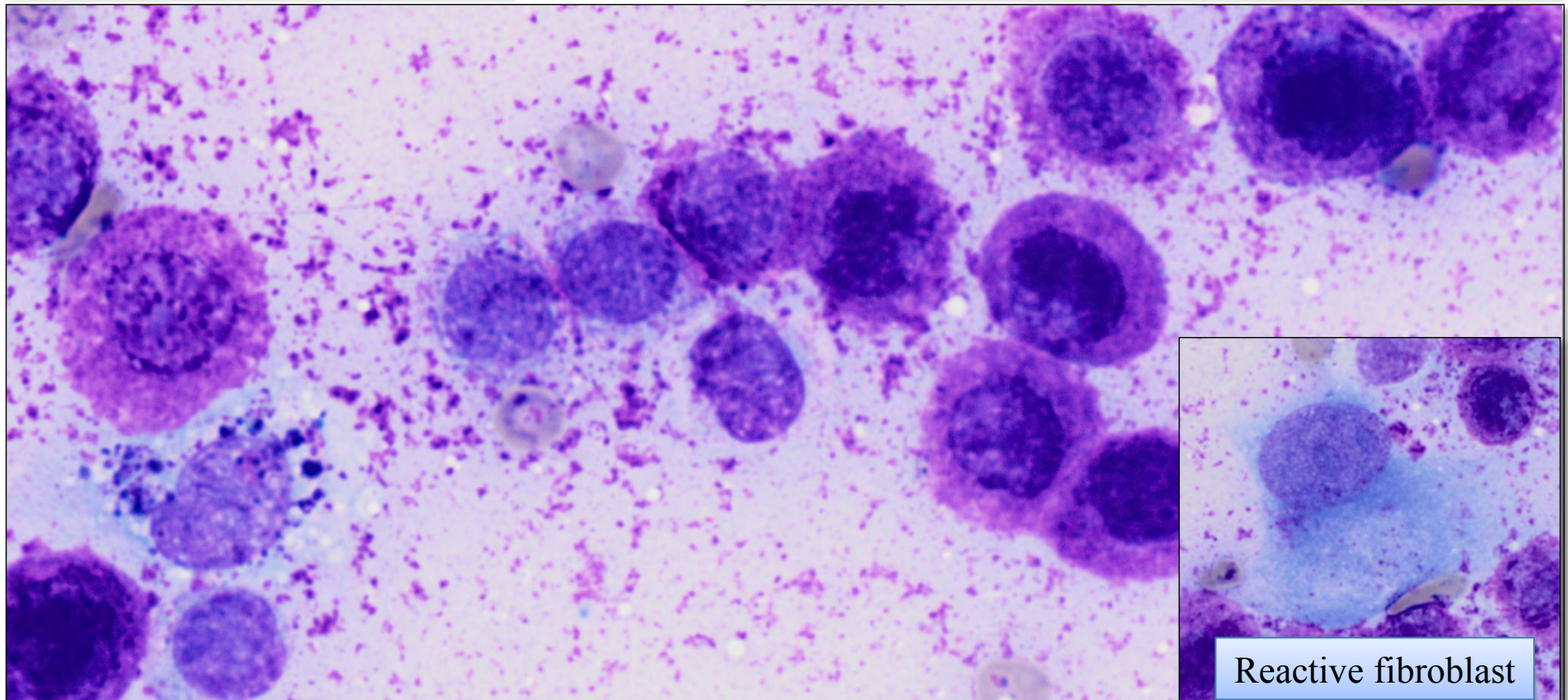
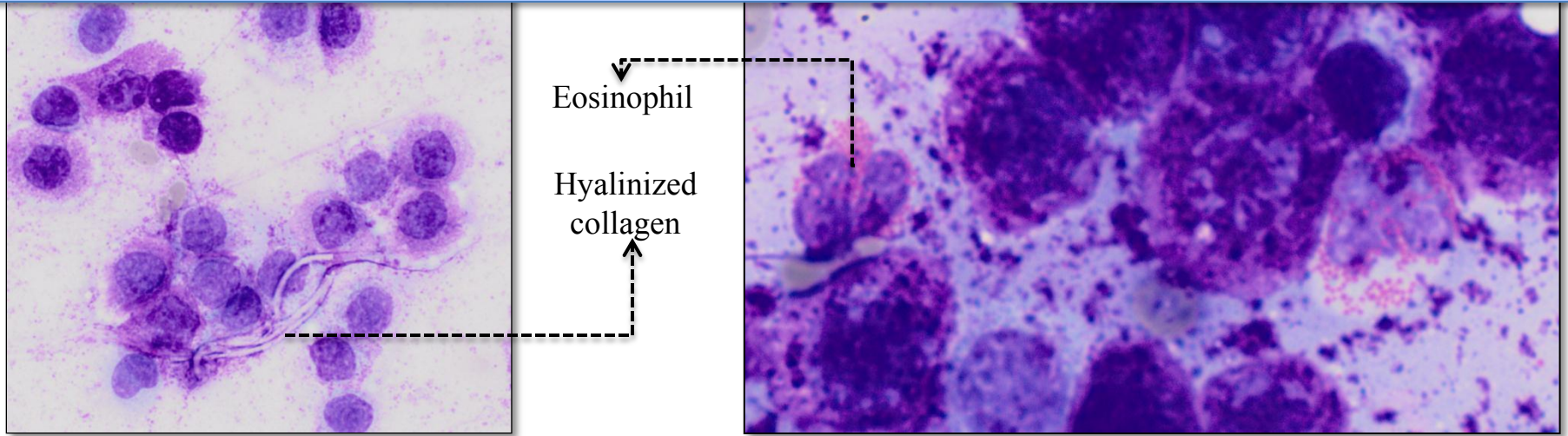
Clinical Pathology



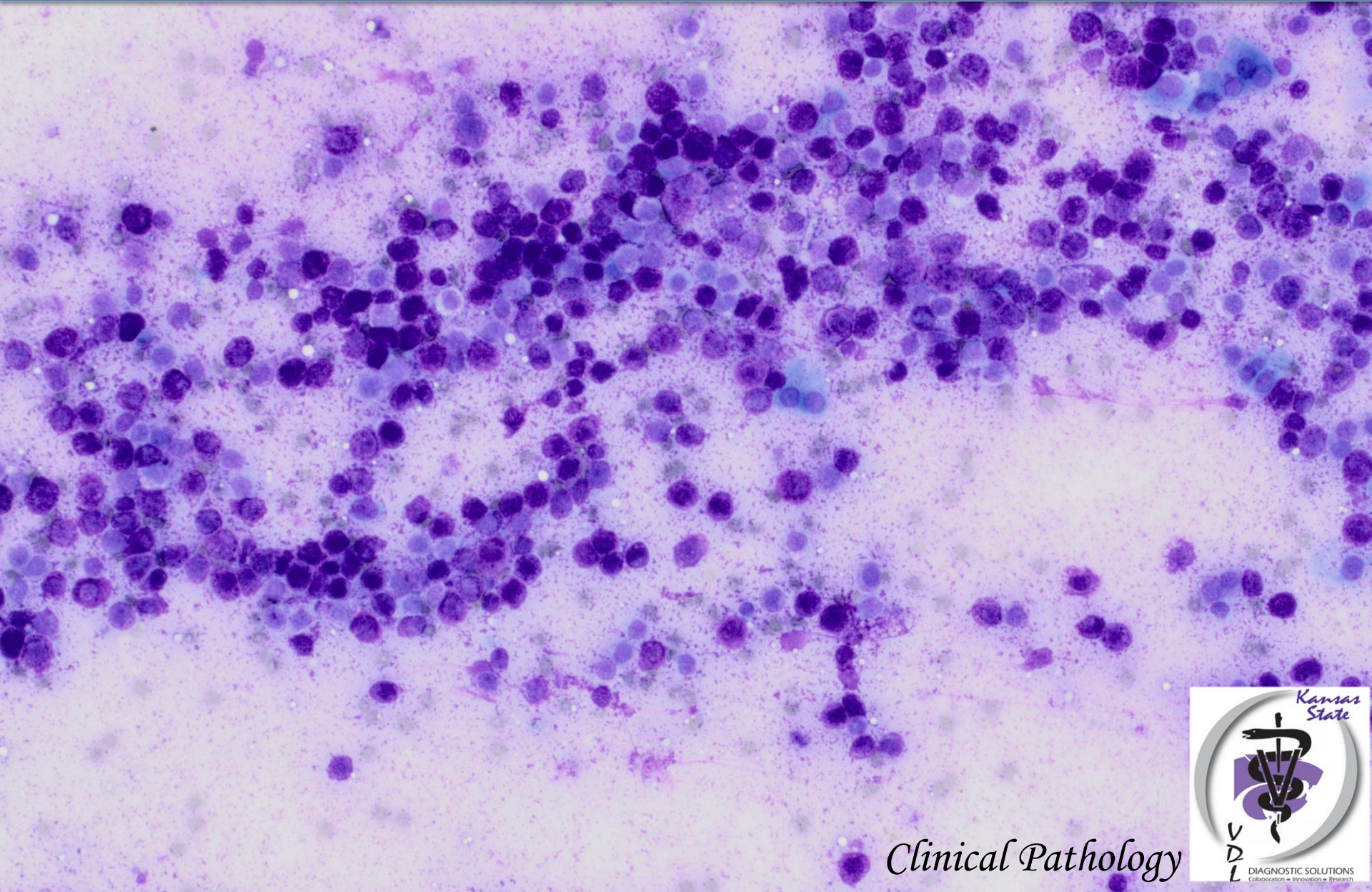
Aspirate from a cutaneous mass in a 7-year-old ferret



Aspirate from a cutaneous mass in a 7-year-old ferret



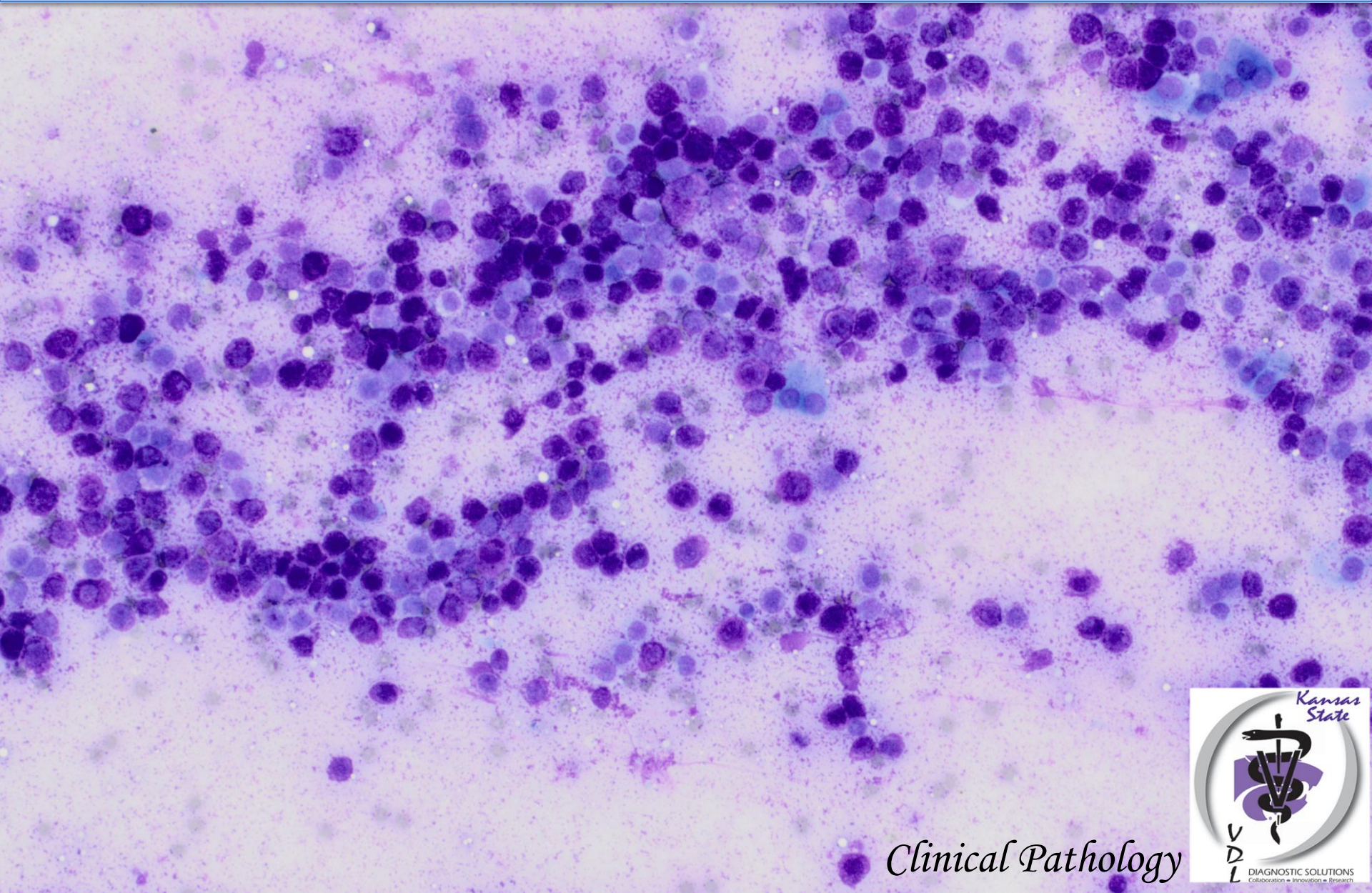
DIAGNOSIS



Clinical Pathology



Mast Cell Neoplasm



Clinical Pathology

