

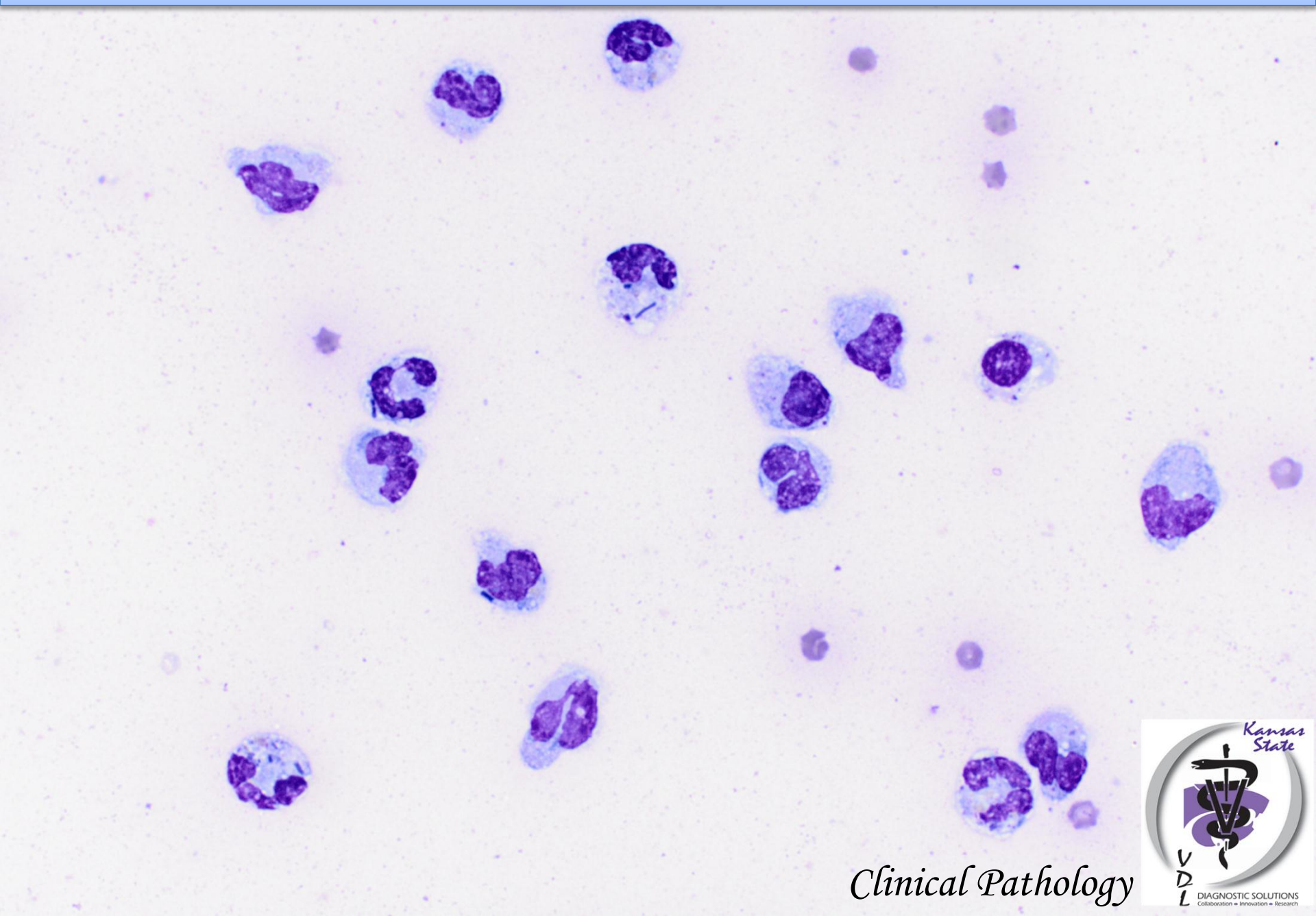
Peritoneal fluid from a 3-day-old foal

Total nucleated cell count: 48,800 / μ L

Hematocrit: < 3%

Protein: 3.6 g/dL

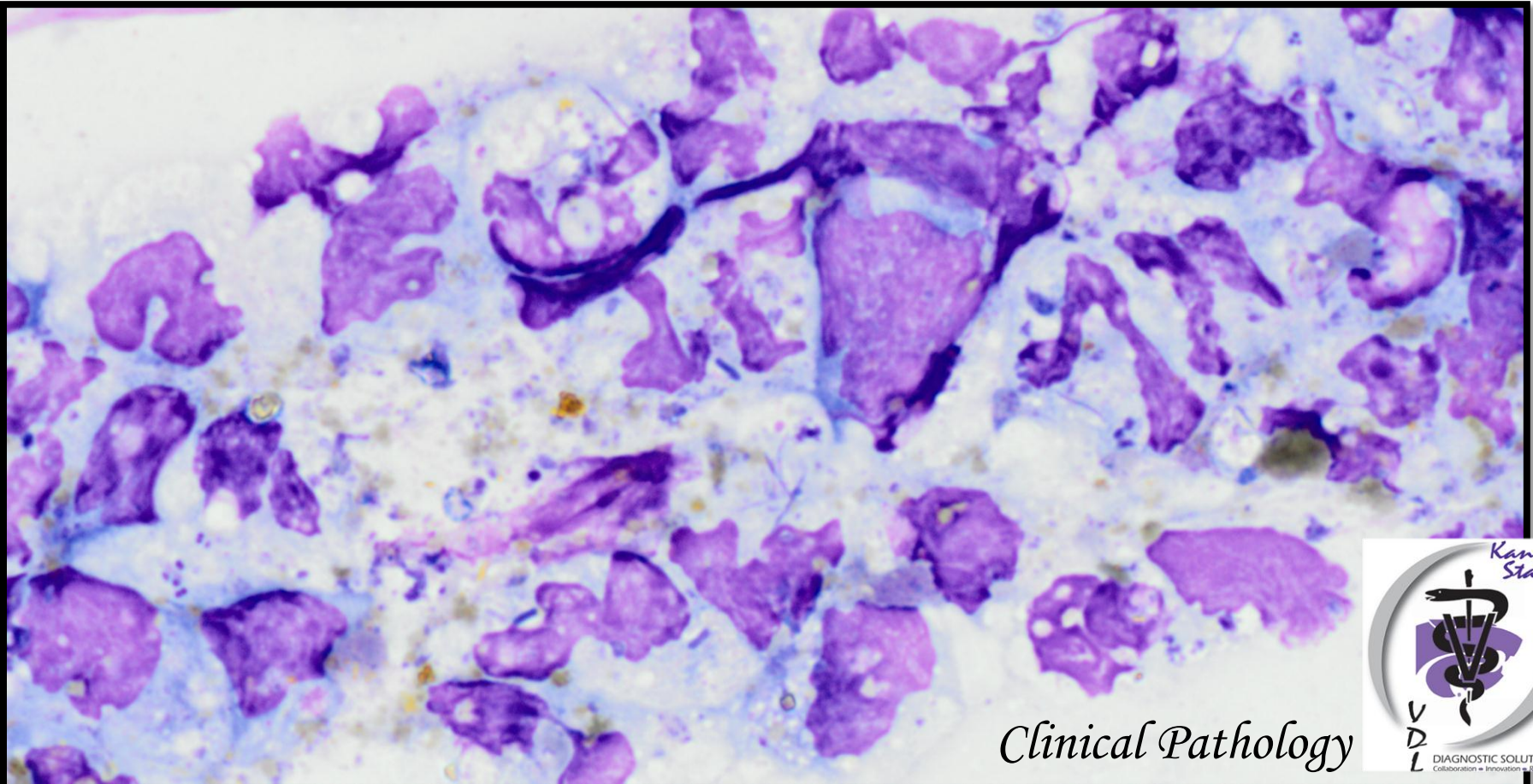
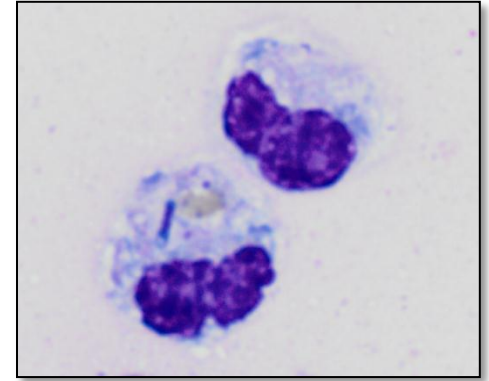
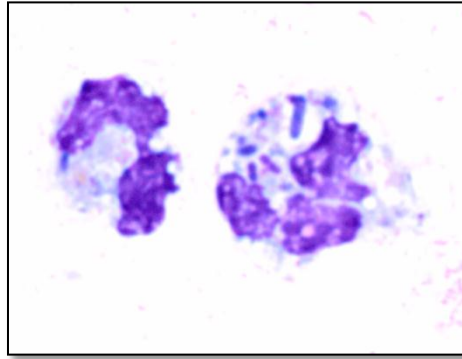
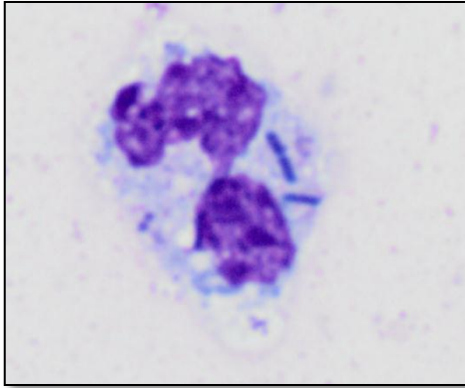
Peritoneal fluid from a 3-day-old foal



Clinical Pathology

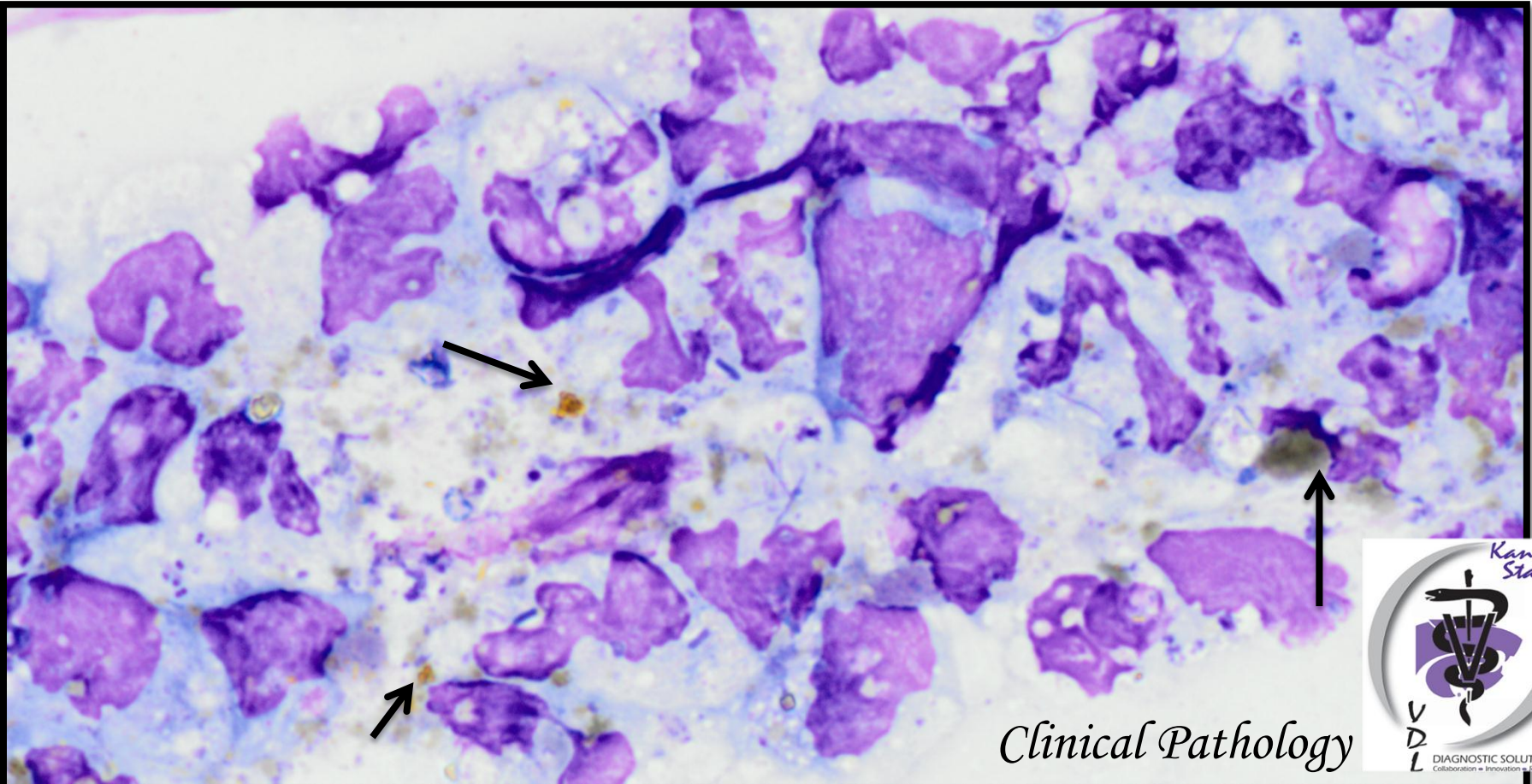
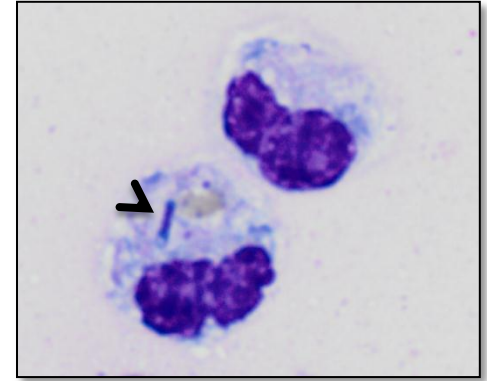
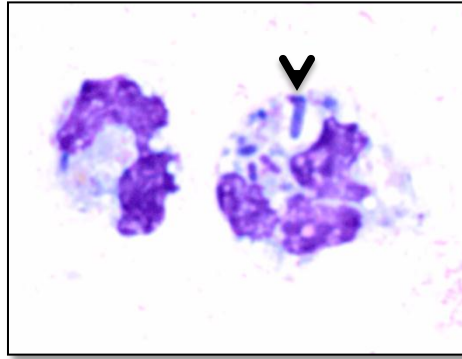
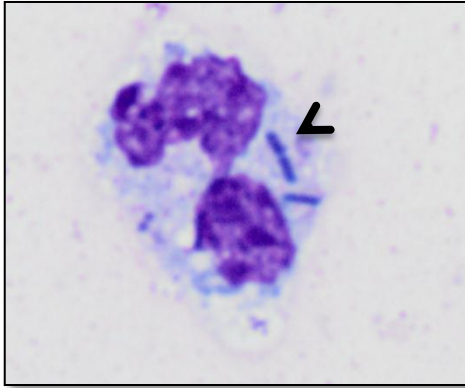


Peritoneal fluid from a 3-day-old foal



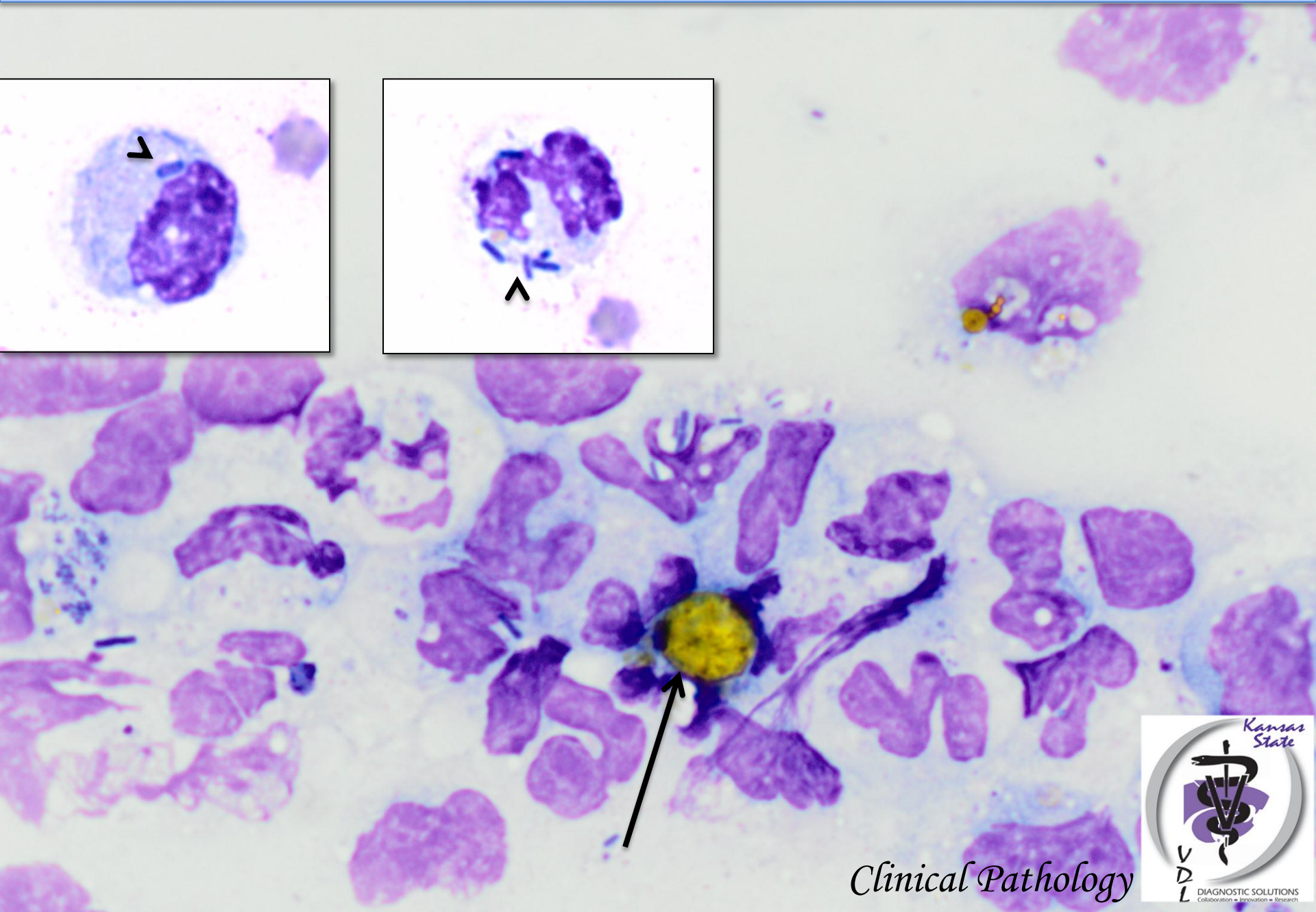
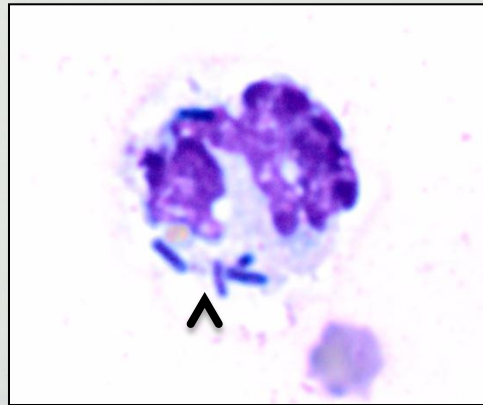
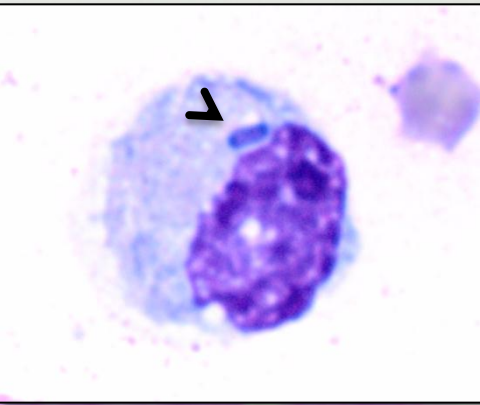
Clinical Pathology

Peritoneal fluid from a 3-day-old foal



Clinical Pathology

DIAGNOSIS



Clinical Pathology



Marked neutrophilic inflammation, septic and meconium pigment

