

# DIAGNOSTIC INSIGHTS

## Outbreak of Canine Influenza Virus in the U.S.

By Dr. Megan Niederwerder

### History

In May 2017, an outbreak of canine influenza virus (CIV) H3N2 was reported in Florida<sup>1</sup> and has increased concerns about this disease throughout the U.S. CIV cases associated with this outbreak have now been reported in several states, including Florida, Minnesota, Georgia, Tennessee, Texas, North Carolina, South Carolina, Kentucky, Missouri, Louisiana, and Illinois. Although CIV infection typically results in high morbidity (80% of dogs infected show clinical signs), the mortality rates are fairly low (< 10%). A recent news release from a University of Florida veterinarian reported that at least 82 dogs in Florida have been confirmed as positive for CIV since the outbreak began in May 2017 and that at least 4 of these dogs have died.<sup>2</sup>

### Clinical signs

CIV primarily infects dogs, but has the potential to be transmitted to cats.<sup>3</sup> Clinical signs are typical of respiratory infections, and include sneezing, coughing, and oculonasal discharge. Nonspecific clinical signs may include lethargy, inappetance and mild to moderate fever. Most infected dogs resolve clinical signs uneventfully and do not require veterinary intervention. In a small number of cases, pneumonia may develop, typically with a secondary bacterial infection, and clinical signs may progress to dyspnea, tachypnea, and high fever. Dogs that develop pneumonia may require hospitalization, intravenous drug therapy, supplemental oxygen and intensive supportive care.

### *In this Issue*

CIV Outbreak	1
Blue-green Algae	2
Feline dermatitis	3
KS Anaplasmosis Study	4
KSVDL on YouTube	4
New Diagnostic Case Report	5
KSVDL Activities	5
CE and Holiday Schedule	6

*Accredited by the American  
Association of Veterinary  
Laboratory Diagnosticians*

**TO SET UP AN ACCOUNT GO TO:**  
[www.ksvdl.org/accounting-and-billing/](http://www.ksvdl.org/accounting-and-billing/)

### Shedding and Vaccination

Dogs shed CIV in nasal and respiratory secretions post-infection and the virus is highly transmissible among canine populations in close contact. Although shedding is thought to be highest within the first four days post-infection, it is recommended that exposed dogs are isolated for four weeks, due to the possibility of intermittent and persistent shedding. Inactivated vaccines are available for CIV; vaccination is classified as risk-based by the American Animal Hospital Association and should be considered based on exposure risk, such as dogs who are boarded, travel, participate in dog shows, or visit dog parks frequently.

*Continued on next page*

## Canine Influenza Virus (continued)

### Diagnostics

Diagnosis is typically completed through the detection of CIV nucleic acid on PCR of nasal swabs. It is ideal to collect nasal swabs at the onset of clinical signs or shortly thereafter. Lung tissue can also be tested by PCR for post-mortem diagnosis. KSVDL has an influenza PCR and also includes CIV on the Canine Respiratory Panel (together with adenovirus-2, herpesvirus-1, distemper virus, parainfluenza virus-3, respiratory coronavirus, Mycoplasma spp., and Bordetella bronchiseptica). Swabs should be submitted using 0.25 ml sterile saline, viral transport media, or the Copan-Eswab™ system.

For more information on CIV, visit the AVMA website<sup>4</sup> or contact KSVDL at [clientcare@vet.k-state.edu](mailto:clientcare@vet.k-state.edu) or 866-512-5650.

### References:

- <sup>1</sup> University of Florida. 2017. "Statement from the University of Florida College of Veterinary Medicine Regarding Canine Influenza H3N2." <https://vetmed-hospitals.sites.medinfo.ufl.edu/files/2017/05/UFCVM-Canine-Influenza-Statement-May-31.pdf>
- <sup>2</sup> Santich, Kate. 2017. "As dog flu outbreak widens, experts call for flu shots." <http://www.orlandosentinel.com/news/os-dog-flu-101-central-florida-20170628-story.html>
- <sup>3</sup> University of Wisconsin-Madison. 2016. "UW Shelter Medicine, WVDL find canine influenza transmitted to cats in Midwestern shelter." <http://www.uwsheltermedicine.com/news/2016/3/uw-shelter-medicine-wvdl-find-canine-influenza-transmitted-to-cats-in-midwestern-shelter>
- <sup>4</sup> American Veterinary Medical Association. 2017. "Canine Influenza." <https://www.avma.org/KB/Resources/Reference/Pages/Canine-Influenza-Backgrounder.aspx>

# Blue-green Algae: Be Aware of the Risks

By Dr. Deon van der Merwe


Along with long summer days and warm weather, the blue-green algae bloom season is in full swing in Kansas, and it is again necessary consider the risks when people and animals access lakes and ponds.

Excess nutrients in ponds and lakes, in combination with warmth and sunlight, make it possible for cyanobacteria (also known as blue-green algae) to multiply exponentially, leading to discoloration of the water and/or the formation of scums, a condition known as a HAB (harmful algal bloom). HABs have the potential to generate dangerous toxins that can sicken or even be deadly to people and animals. Some of the toxins can be irritating to the skin and mucous membranes. Inhalation of water droplets, for example when swimming or water skiing, can cause irritation in the airways. Ingestion of affected water is, however, the most dangerous form of contact. It can lead to severe gastrointestinal inflammation with vomiting and diarrhea, and absorption into the rest of the body may lead to life threatening adverse effects in the liver and the nervous system.

Not all types of blue-green algae or other causes of water discoloration and scums produce toxins, but if such conditions are encountered it is best to assume that the water could be dangerous until its safety can be confirmed.

If water discoloration or scums are encountered at a publicly accessible lake, please contact the HAB Hotline (785-296-1664) established by the Kansas Department of Health and Environment (KDHE), or file a report on their website: <http://www.kdheks.gov/algae-illness>.

For private lakes and ponds, samples may be sent to the KSVDL for testing. For more information, please call KSVDL Client Care at 866-512-5650.



*Blue-green algae "bloom" or "scum"*

## Feline idiopathic ulcerative dermatitis: What do we know to date?

### Disease condition

Feline idiopathic ulcerative dermatitis is a rare skin disease seen exclusively in cats with a classic presentation characterized by large non-healing ulcerations on the dorsal midline of the caudal neck and beyond the ears (See figure 1). On clinical presentation, these lesions are usually solitary, starting as a focal area of alopecia progressing to erythema and ulceration. The presence of pain and pruritis is variable, but can be seen as the cat intermittently and maniacally self-traumatizes the lesion. Only regional lymphadenopathy will be noticed with no systemic signs. There is no age, breed or gender specificity associated with this condition.

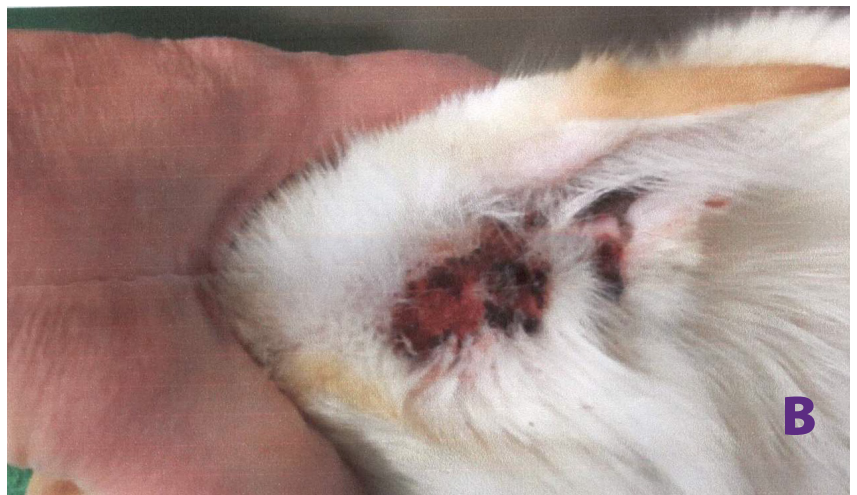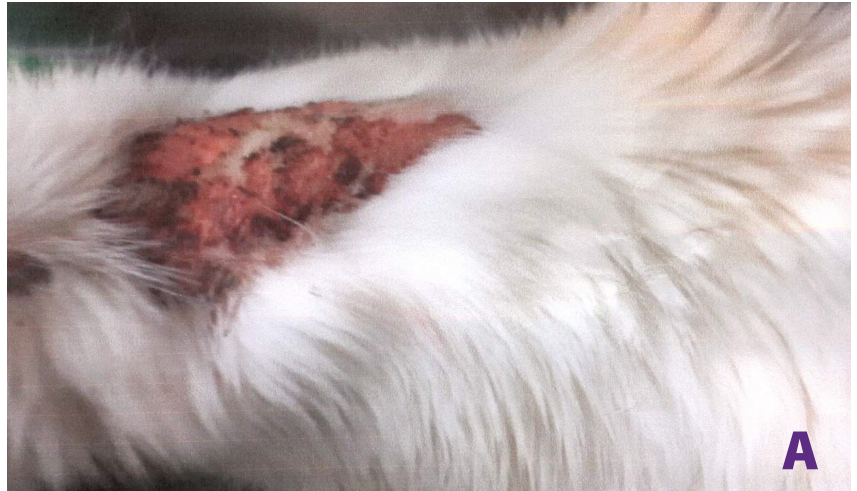### Etiology

As “idiopathic” suggests in the name, feline idiopathic ulcerative dermatitis has no known etiology. Previous reports suggest it occurs secondary to injection-site reactions but there are several cases reported where similar lesions have developed with no history of injections. It is speculated that the location where lesions occur undergoes hyperstimulation of nerve endings (neuropathic itch syndrome).

### Diagnosis

Differential diagnoses include physical or chemical injury, injection-site reactions, foreign bodies, fungal, bacterial and viral infections, *Demodex gatoi* infestation, hypersensitivity disorders and neoplasia.

The clinical presentation of lesions is very unique with large focal ulcerative lesions on the dorsal midline of the distal neck or between the scapula and in some cases extend beyond the ears. A biopsy taken from the margin of the lesion including ulcerated and non-ulcerated areas will be helpful in a definitive diagnosis. Histologically, the epidermis is markedly ulcerated with necrosis that extends to the



**Figure 1:** Feline Idiopathic Ulcerative Dermatitis in a 15-year-old male neutered cat. There is a deep ulcer on the caudal dorsal neck area (A) and behind the ears bilaterally (B)

superficial dermis. The intact epidermis along the margins of the lesion show epidermal hyperplasia with little to no dermal inflammation (Figure 2 (next page)). In chronic cases ranging from 6 months to 1 year, there will be classic subepidermal linear fibrosis observed.

### Management

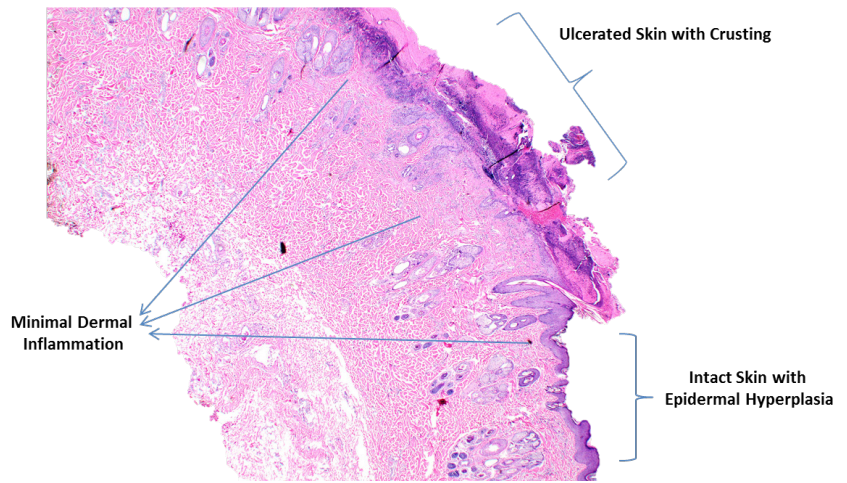
The prognosis is guarded to poor because lesions are often refractory to medical treatment and may be too extensive for surgical resection. To date there have been two published reports available

*Continued on next page*

**Feline idiopathic ulcerative dermatitis (continued)**

on the treatment of this condition. I recommend reading the following articles:

1. Topiramate in the management of feline idiopathic ulcerative dermatitis in a two-year-old cat David Grant and Clare Rusbridge. *Vet Dermatol* 2014; 25: 226.
2. Feline idiopathic ulcerative dermatosis treated successfully with Oclacitinib. Conference Paper · April 2015 North American Veterinary Dermatology 2015, At Nashville, TN, USA.



**Figure 2:** Marked ulceration with crusting with acute transition to intact skin showing epidermal hyperplasia with very minimal dermal inflammation

**Acknowledgements**

We thank Dr. Vickie Smith, Smith Veterinary Clinic, Tonganoxie, KS, for submitting this case to KSVDL and allowing us to publish the gross images.

**Kansas Anaplasmosis Study Update**

Thanks again to all the veterinarians and their clients who participated in the state-wide study. We ended up with samples from close to 900 herds!!

The testing has been delayed, but we are hopeful results will be forth coming.

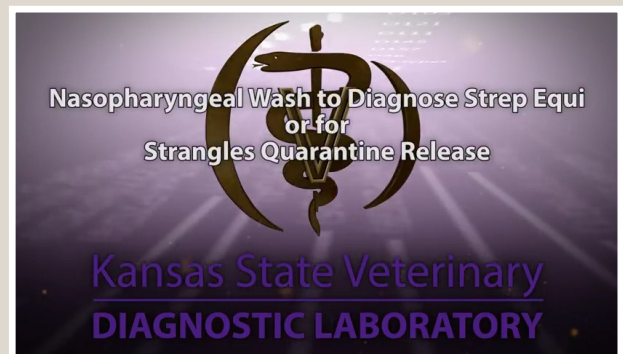
Originally, the goal was to have all sampling completed by January 31st so results could be forwarded to producers took their herds to grass. KSVDL extended the sampling period two more months because herds were late pregnancy checking, and we wanted to give as many herds possible the opportunity to participate.

This extension has delayed our third party laboratory from completing the testing as we would have liked.

We are hopeful the results will be available within the next couple of weeks. As soon as we receive them, we will forward the results to you.

Thanks again for your participation.

**New Videos: KSVDL  
YouTube Channel**



<https://www.youtube.com/channel/UCtx-IIIxqj5PAMQYryXaRhA>

- Nasal swab sampling in horses
- Nasopharyngeal wash for Strep. equi screening

**For more information please contact  
KSVDL Client Care at 866-512-5650  
or [clientcare@vet.k-state.edu](mailto:clientcare@vet.k-state.edu).**

## Check out our new DIAGNOSTIC CASE REPORT publication

Every three months, the KSVDL publishes this report which includes interesting cases from multiple species that the KSVDL team has been involved with.

To view the April version, please follow this link: [http://www.ksvdl.org/reports/april\\_2017/index.html](http://www.ksvdl.org/reports/april_2017/index.html)

Lineup for the August Edition:

- Purebred beef herd summer pneumonia
- Equine Streptococcus equii
- Feline tularemia
- Bovine Ionophore toxicity



## KSVDL Personnel Publications and Activities

### Publications

- A porcine enterovirus G associated with enteric disease contains a novel papain-like cysteine protease. Knutson TP, Velayudhan BT, **Marthaler DG**. Journal General Virology. 2017 Jun;98(6):1305-1310
- Bacterial flora of liver abscesses in crossbred beef cattle and Holstein steers fed finishing diets with or without tylosin. Amachawadi RG, **Purvis TJ, Lubbers BV**, Homm JW, Maxwell CL, Nagaraja TG. Accepted: *Journal of Animal Science*
- Transient Bovine Viral Diarrhea Virus (BVDV) infections in cattle that are experimentally exposed to cattle persistently infected (PI) with BVDV. **Lalitha Peddireddi**, Kelly A. Foster, **Elizabeth G. Poulsen, Baoyan An**, Quoc Hung Hoang, Catherine O'Connell, **Joseph W. Anderson**, Daniel U. Thomson, **Gregg A. Hanzlicek, Jianfa Bai, Richard A. Hesse**, Richard D. Oberst, **Gary A. Anderson** Accepted: *Journal of Veterinary Diagnostic Investigations*
- Genotypic and epitope characteristics of group A porcine rotavirus strains circulating in Canada. Naseer O, Jarvis MC, Ciarlet M, **Marthaler DG**. Virology. 2017 Jul;507:53-63
- A novel RNA-based in situ hybridization to detect Seneca Valley virus in neonatal piglets and sows affected with vesicular disease Resende TP, **Marthaler DG**, Vannucci FA. PLoS One. 2017 Apr 10;12(4)

### Activities

- Dr. Brian Lubbers was appointed to the Food Armor® Foundation Board of Directors.
- Dr. Gary Anderson attended the World Association of Veterinary Laboratory Diagnosticians in Sorrento, Italy.
- Dr. Doug Marthaler presented poster illustrating development and validation of a multiplex real time RT-PCR to detect Porcine Epidemic Diarrhea Virus, Transmissible Gastroenteritis Virus, and Porcine Deltacoronavirus at the World Association of Veterinary Laboratory Diagnosticians in Sorrento, Italy.
- Dr. Doug Marthaler attend the American Society for Virology in Madison, WI.

### Field Investigations

- Dr. Gregg Hanzlicek and 4th year KSU-CVM student Ben Bennett investigated a mastitis issue on a Kansas dairy.

## Developing and Delivering Accurate, Innovative Diagnostic Services

*The mission of the Kansas State Veterinary Diagnostic Laboratory (KSVDL) is to develop and deliver accurate, innovative, and timely diagnostic and consultative services to the veterinary and animal health community while providing support for teaching, training and research programs.*

**1800 Denison Avenue  
Manhattan, KS 66506**

**Phone: 785.532.5650  
Toll Free: 866.512.5650**

### Continuing Education

[www.vet.k-state.edu/education/continuing/](http://www.vet.k-state.edu/education/continuing/)

#### **July 21-25, 2017**

##### **American Veterinary Medical Association Annual Convention**

Indianapolis Convention Center  
Indianapolis, Indiana  
[https://www.avma.org/Events/Convention/  
Pages/default.aspx](https://www.avma.org/Events/Convention/Pages/default.aspx)

#### **August 25-28, 2017**

##### **CVC Kansas City**

Kansas City, Missouri  
<http://www.thecvc.com/cvc-kc-at-a-glance/>

#### **September 13-16, 2017**

##### **American Association of Bovine Practitioners Conference**

Omaha, Nebraska  
<http://www.aabp.org/meeting/>

For more information, call the Continuing Education Office  
at 785-532-4528.

### Test Results and Schedules

**Laboratory results available  
online, all the time!**

#### **Holiday Schedule:**

**Labor Day:** Closed: Monday, Sept. 4<sup>th</sup>

**Thanksgiving:** Closed Thursday, November  
23<sup>rd</sup> and Friday November 24<sup>th</sup>  
Open: Saturday November, normal  
business hours (8 a.m. to 12 noon)

To receive this newsletter by email,  
contact: [ksvdloutreach@vet.k-state.edu](mailto:ksvdloutreach@vet.k-state.edu).

